

## Case Report:

### Scar endometriosis-a case report with review of literature

Dr. KANDUKURI MAHESH KUMAR , Dr. SUDHIR KUMAR VUJHINI , Dr. RAVIKANTH SONI ,  
Dr. DIVYAGNA. T , Dr. KONDURU OMKARESHWAR

Name of the Institute/college: MALLA REDDY INSTITUTE OF MEDICAL SCIENCES, SURARAM, HYDERABAD.

Corresponding author: Dr. KANDUKURI MAHESH KUMAR , ASSISTANT PROFESSOR, MALLA REDDY INSTITUTE OF MEDICAL SCIENCES, SURARAM , HYDERABAD-500055 , India

Date of submission: 28 June 2014; Date of Publication: 25 September 2014

---

#### ABSTRACT

Endometriosis is defined as the presence of endometrial tissue apart from its usual location (endometrium). Endometriosis predominantly seen on peritoneal surfaces/structures such as the ovaries, posterior cul-de-sac, and ligaments of the uterus, pelvic peritoneum and rectovaginal septum and is found in 8%–15% of all menstruating women. Sometimes endometriosis also affects the vagina, vulva and perineum, usually secondary to surgical or obstetric trauma. Extra-pelvic endometriosis is less common but can affect many sites, including the lungs, appendix, nose, umbilicus, peritoneum and even the intestinal wall. The most common extra-pelvic form of endometriosis is cutaneous endometriosis, mainly in scars following obstetric or gynecologic surgery. Surgical scar endometriosis following cesarean section has an incidence of 0.03%–0.4%. Scar endometriosis is often mistaken for a suture granuloma, incisional hernia, lipoma, abscess, cyst or a foreign body reaction, diagnosis of this disease is not easy. However, a mass in a

Caesarean section scar with symptoms of cyclic pain related to menses is nearly pathognomonic of scar endometriosis. We report a case of scar endometriosis in a 28 year old female with previous two caesarian sections and complaints of cyclical bleeding from the scar.

**KEYWORDS:** Scar Endometriosis, Cutaneous, Extra-pelvic, Incisional Endometriosis

---

#### INTRODUCTION

Endometriosis is defined as the presence or growth of ectopic endometrial tissue. The current prevalence of endometriosis according to the recent statistics is 89 million cases. Women of reproductive age are most commonly affected worldwide. However, extra pelvic endometriosis is a fairly uncommon disorder and difficult to diagnose. The various sites for extra pelvic endometriosis are bladder, kidney, bowel, omentum, lymph nodes, lungs, pleura, extremities, umbilicus, hernial sacs, and abdominal wall <sup>(1)</sup>. Abdominal wall endometriosis often develops in previous surgical scars but there is a case report of a

spontaneous occurrence also <sup>(2)</sup>. Majority of the scar endometriosis have been reported after obstetrical or gynecological procedures such as cesarean delivery, hysterotomy, hysterectomy, episiotomy, and tubal ligations, <sup>(3, 4, 5)</sup> but few case reports are following appendectomy, in the laparoscopic trocar tract, amniocentesis needle tract. Scar endometriosis patients are often referred to the general surgeons because the clinical presentation suggests a surgical cause. In a study by Blanco et al <sup>(6)</sup> the diagnosis was initially confused with inguinal hernia, incisional hernia and abdominal wall tumor. This paper is presented to report the rare incidence of scar

endometriosis, to review the literature and increase the awareness regarding this rare condition, which is often misdiagnosed.

#### CASE REPORT

A 28 year old lady came with complaints of cyclical bleeding from the caesarean scar and associated with pain since one and half year. There was gradual increase in amount of bleeding and pain at the incisional site with every cycle. She gave history of uncomplicated lower segment caesarean section 3 years ago. General Physical examination revealed a well-healed caesarian scar, with a non-mobile, tiny multiple nodules, moderately pigmented areas. Length of the caesarian scar was 13cm. Tenderness on palpation over the nodular areas were noted. Ultrasonography was non-contributory with an impression- possibility of endometriosis.

Tiny nodules over the caesarian scar were excised and sent for histopathological examination.

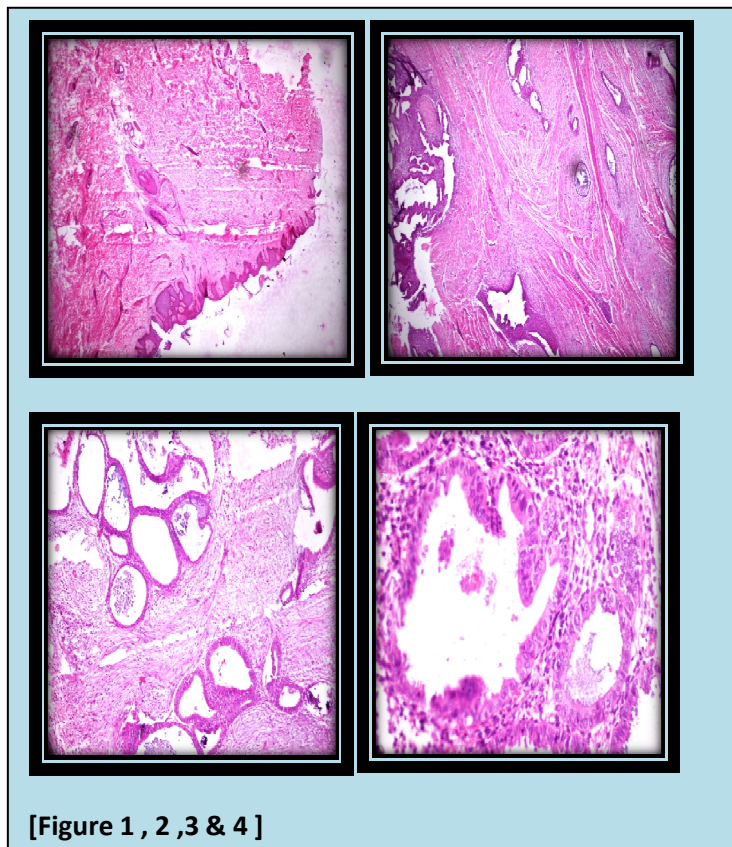
#### HISTOPATHOLOGICAL EXAMINATION

##### Gross Examination

We received multiple gray brown to gray black fragmented soft tissue bits altogether measuring 1 x 0.8 cm.

##### Microscopy

Multiple sections studied show structure of skin with epidermis and dermis. Dermis shows few hair follicles, endometrial glands and stroma. Endometrial glands round to oval, few are elongated tortuous and cystically dilated and are lined by columnar to low cuboidal epithelium with nuclear stratification. Cystically dilated glands are filled with secretions and showing cyst macrophages. At places glands are showing back to back arrangement. Stroma is fibrocollagenous and showing non-specific inflammatory cells with few congested blood vessels.



[Figure 1 , 2 ,3 & 4 ]

## DISCUSSION

Extra-pelvic endometriosis, though uncommon, can occur in subcutaneous tissues of surgical scars, or in the surrounding areas, following obstetric and gynecological procedures. These implants are more likely to occur as a consequence of procedures performed during gestation including Caesarean section and normal delivery (episiotomy scar) or as a consequence of procedures that involved endometrial tissue, such as hysterectomy, ectopic pregnancies, salpingostomies and those performed during the first half of the pregnancy (7,8,9,10,11,12). Several mechanisms can explain the incidence of scar endometriosis. Direct implantation of endometrial cells at the time of the operation is the dominant explanation. The lack of secure closure of the parietal and visceral peritoneum during Caesarean section and reduced care to avoid dissemination of endometrial cells may also be associated with endometriosis at the surgical scar. This scenario, however, is rare and the increased incidence is seen particularly after Caesarean section (0.03%). Metaplasia of peritoneal mesothelial cells which remain in the incision during the initial operation has also been reported. The theories of lymphatic or vascular dissemination, as well as retrograde menstruation are not widely accepted. Finally, the recent hypothesis that the presence of endometriosis is related to immuno-genetic defects may explain its development *via* inadequate response of the peritoneal defensive system to the retrograde flow or implantation of endometrial tissue. The presence of a mass at the surgical scar, especially after gynecological procedures, with symptoms that accompany menstruation is pathognomonic of

endometriosis. According to reports, scar endometriosis can also mimic a lipoma, a cyst, an abscess or an incisional granuloma (13). The diagnosis of scar endometriosis is difficult to establish purely based on clinical examination. Ultrasonography is non-specific and its main role is to exclude incisional hernia. Computed tomography (CT), Magnetic Resonance Imaging (MRI), ultrasonography and Fine Needle Aspiration Cytology (FNAC) have been reported as diagnostic with variable results. Therapy with oral contraceptives, progestin's, medroxy - progesterone acetate and gonadotropin-releasing hormone agonists has been tried with minimal success. In some patients, the effects can be relatively long-lasting, but complete, permanent regression of endometriosis is rare with medical therapy. For cutaneous endometriosis, total surgical excision is considered to be the gold standard for both diagnosis and treatment. Resection must be complete with clear healthy margins to prevent recurrence.

## CONCLUSION

Cesarean section incisional endometriosis is very rare and difficult to diagnose. In addition, it is an underappreciated phenomenon in general surgery, so it may be more common than reflected in the literature. Familiarity with its signs and symptoms will increase awareness of this disease.

Endometriosis should be included in the differential diagnosis of abdominal scar lesions following gynecological operations. A mass involving cesarean section scars with symptoms intensifying before each menses is almost pathognomonic. Medical treatment may decrease symptoms for some time; however, to provide both diagnostic and therapeutic intervention, surgical management is the gold standard treatment.

## REFERENCES

1. Markham SM, Carpenter SE, Rock JA. Extra pelvic endometriosis. *Obstet Gynecol Clin North Am* 1989;16:193-219.
2. Ideyi SC, Schein M, Niazi M, Gerst PH. Spontaneous endometriosis of the abdominal wall. *Dig Surg* 2003;20:246-8.
3. Padmanabhan LD, Mhaskar R, Mhaskar A. Scar endometriosis. *J Obstet Gynaecol India* 2003;53:59-61.
4. Bhowmick RN, Paul P, Dutta S, Roy B. Endometriosis of laparotomy scar. *J ObstetGynaecol India* 1986;36:130-2.
5. Chatterjee SK. Scar endometriosis: A Clinicopathological study of 17 cases. *Obstet Gynecol* 1980;56:81-4.
6. Blanco RG, Parithivel VS, Shah AK, Gumbs MA, Schein M, Gerst PH. Abdominal wall endometriomas. *Am J Surg* 2003;185:596-8.
7. Taff L, Jones S. Cesarean scar endometriosis. A report of two cases. *J Reprod Med* 2002; **47**: 50–2.
8. Tica VI, Tomescu CL, Micu L, Zaher M, Bafani S, Beghim M, et al. Asymptomatic abdominal wall endometrioma 15 years after cesarean section. *Rom J Morphol Embryol* 2006; **47**: 301–4.
9. Apostolidis S, Michalopoulos A, Papavramidis TS, Papadopoulos VN, Paramythiotis D, Harlaftis N. Inguinal Endometriosis: Three cases and literature review. *South Med J* 2009; **102**: 206–7.
10. Sataloff DM, LaVorgna KA, McFarland MM. Extrapelvic endometriosis presenting as a hernia: clinical reports and review of the literature. *Surgery* 1989; **105**: 109–12.
11. Picod G, Boulanger L, Bounoua F, Leduc F, Duval G. Abdominal wall endometriosis after cesarean section: Report of fifteen cases. *Gynecol Obstet Fertil* 2006; **34**: 8–13.
12. Nominato NS, Prates LF, Lauar I, Morais J, Geber S. Cesarean section greatly increases risk of scar endometriosis. *Eur J Obstet Gynecol* 2010; **152**: 83–5.
13. Sengul I, Sengul D, Kahyaoglu S, Kahyaoglu I. Incisional endometriosis: A report of 3 cases. *Can J Surg* 2009; **52**: 444–5.